

The osteodystrophy of mucopolidosis type III and the effects of intravenous pamidronate treatment

C. ROBINSON¹, N. BAKER¹, J. NOBLE¹, A. KING², G. DAVID³,
D. SILLENCE³, P. HOFMAN⁴ and T. CUNDY^{4*}

¹Department of Paediatrics, Nelson Hospital, Nelson; ²Department of Pathology, Middlemore Hospital, Auckland, New Zealand; ³Academic Department of Medical Genetics, The Children's Hospital, Westmead, Australia; ⁴Faculty of Medicine & Health Sciences, University of Auckland, Auckland, New Zealand

*Correspondence: Department of Medicine, Faculty of Medicine & Health Sciences, University of Auckland, Private Bag 92019, Auckland 1, New Zealand.

E-mail: t.cundy@auckland.ac.nz

MS received 14.10.02 Accepted 15.11.02

Summary: Mucopolidosis type III (ML III; McKusick 252600) is a rare lysosomal storage disease in which skeletal involvement is prominent, in particular the destruction of vertebral bodies and the femoral heads. We describe studies in two siblings with ML III that suggest the presence of a distinct metabolic bone disorder. Biochemical indices of bone turnover were increased, and transiliac bone biopsy demonstrated both trabecular osteopenia and marked subperiosteal bone resorption. Intravenous pamidronate treatment given monthly for a year was well tolerated and produced dramatic clinical effects, with reduction in bone pain and improvements in mobility, despite incomplete suppression of bone resorption as assessed by biochemical, radiographic and histological criteria. Bisphosphonate therapy may have an important role in the management of bone pain in ML III, as it does in the related lysosomal disorder of Gaucher disease.

Mucopolidosis type III (McKusick 252600, also known as pseudo-Hurler polydystrophy) is a recessively inherited lysosomal storage disease. These disorders arise from defects in lysosomal enzymes responsible for the breakdown of complex molecules, such as glycosaminoglycans. Tissue damage develops as a result of the accumulation of incompletely processed macromolecules. The differing clinical phenotypes of the lysosomal storage disorders reflect the enzyme that is defective, the products that accumulate, and the particular tissues in which they accumulate. In the case of mucopolidosis type III, which was first described by Maroteaux

and Lamy (1966), the defective enzyme is *N*-acetylglucosaminyl 1-phosphotransferase. This enzyme is important in the posttranslational modification of several lysosomal enzymes. It adds a mannose 6-phosphate recognition marker that permits the enzyme to be transported into lysosomes (and, to a lesser extent, permits the reuptake of enzyme into lysosomes from the extracellular milieu). Within the lysosome, further posttranslational modification of the enzymes takes place and the acid environment is necessary for enzymatic function. In the absence of the mannose 6-phosphate marker, the enzymes are not taken up into lysosomes and readily 'leak' out of cells. The plasma activities of these enzymes may thus be high, but they are ineffective (Kornfeld and Sly 2001; Reitman et al 1981). Unprocessed glycoproteins and glycolipids accumulate in tissues, giving rise to the clinical manifestations of the disease.

The clinical manifestations of mucopolidosis type III (ML III) include a mild, Hurler-type dystrophy, mild intellectual disability, valvular heart disease and corneal opacities. Orthopaedic and skeletal manifestations are well recognized (Haddad et al 2000; Hetherington et al 1999; Kornfeld and Sly 2001; Melhem et al 1973). These include the constellation of skeletal abnormalities common to the mucopolysaccharidoses known as dysostosis multiplex, and also a progressive hip dysplasia and vertebral abnormalities (Table 1). In this paper we describe two siblings with severe skeletal complications of ML III. Our observations suggest that ML III is characterized by a distinctive high-turnover metabolic bone disorder. These findings, together with reports of beneficial effects of bisphosphonates in another lysosomal storage disorder, Gaucher disease (Cianna et al 1997; Harinck et al 1984; Ostlere et al 1991; Samuel et al 1994), and the absence of any specific treatment for either ML III or its bony sequelae, led us to trial intravenous pamidronate in the siblings.

Table 1 Orthopaedic and skeletal complications of mucopolidosis type III

Stiffness of hands and shoulders
Claw hand deformity
Scoliosis
Short stature
Low iliac wings, shallow acetabular fossa
Erosion of the femoral heads
Valgus deformity of femoral neck
Underdevelopment of posterior elements of dorsal spine
Dysostosis multiplex
<ul style="list-style-type: none"> ● Skull: calvarial thickening, premature suture closure, shallow orbits, abnormal tooth spacing, J-shaped sella ● Spine: anterior hypoplasia of lumbar vertebrae, kyphosis ● Long bones: shortened, wide diaphyses, irregular metaphyses, poorly developed epiphyseal centres ● Clavicles: short, thickened, irregular ● Ribs: narrow at vertebral ends, flat and broad at sternal ends ● Phalanges: shortened, trapezoidal in shape, widened diaphyses

CASE REPORTS

Subject A: This boy was diagnosed at 6 years of age following investigations for symptoms of joint pain and stiffness. The diagnosis of ML III was confirmed on the basis of measurements of lysosomal enzyme activities in plasma and cultured skin fibroblasts (Table 2). Although he had symptoms of joint pain and restricted movement for many years, he remained mobile until adolescence. At the age of 15 years he developed progressive walking difficulties. Magnetic resonance imaging showed an expansion of the extradural tissue anteriorly opposite C2–C7. A cervical decompression was performed, with fusion at C7, but his neurological status continued to deteriorate. He has been effectively paraplegic and wheelchair-bound since. The reason he failed to improve following surgery is not certain. Possible mechanisms include cord compression, intramedullary storage, vertebral collapse or central nervous system degeneration as a result of lysosomal storage. At 18 years of age, subject A was suffering from significant hip and back pain, which was seriously compromising his quality of life, waking him from sleep and interfering with wheelchair transfers.

Subject B: Subject B is the younger sister of subject A. She was diagnosed with ML III at the age of 2 years following her brother's diagnosis (Table 2). By the age of 12 years she was also suffering from significant, constant joint pain, mainly from the hips. This was accompanied by a dramatic deterioration in her mobility. By age 14 years she was barely able to walk 5 metres and was spending most of her time in a wheelchair.

Both subjects A and B had tried several forms of oral analgesia in an attempt to decrease their hip and back pain. These had all been unsuccessful. In light of experience suggesting beneficial effects of bisphosphonates in relieving bone pain in osteopenic disorders (Astrom and Soderhall 1998; Brumsen et al 1997; Glorieux et al 1998; Landsmeer-Beker et al 1997; Zacharin and Cundy 2000), fibrous dysplasia (Chapurlat et al 1997; Lala et al 2000) and Gaucher disease (Cianna et al 1997; Harinck et al 1984; Ostlere et al 1991; Samuel et al 1994), we elected to treat both subjects with pamidronate, a second-generation aminobisphosphonate.

METHODS

Lysosomal enzyme activity was measured in blood samples (in both plasma and leukocytes), and in cultured skin fibroblasts (in both cells and the supernatant), by the Australian National Lysosomal Diseases Reference Laboratory (Women's and Children's Hospital, Adelaide, South Australia). Total plasma alkaline phosphatase activity and plasma osteocalcin (Nichols Diagnostics, San Clemente CA, USA) were used as the main markers of bone formation. The fasting urine ratios of hydroxyproline/creatinine and *N*-telopeptide/creatinine (breakdown products of type I collagen) were used as markers of bone resorption. Urinary *N*-telopeptide was measured using the Osteomark NTx assay (Ostex International Inc., Seattle, WA, USA).

Bone age was determined from hand radiographs by the method of Tanner and Whitehouse (1983). The combined cortical width of the second metacarpal was

Table 2 Lysosomal enzyme studies

Enzyme	Peripheral blood						Fibroblast culture					
	Plasma (nmol/min per ml)			Leukocytes (nmol/min per mg protein)			Extracellular (nmol/min per ml)			Intracellular (nmol/min per mg protein)		
	A	B	NR ^a	A	B	NR	A	B	NR	A	B	NR
β-Hexosaminidase	335	250	7-42	20	34	10-40	130	169	3-10	17	32	24-123
β-Glucuronidase	15	12	0.1-2	1.0	1.4	0.5-3.4	-	-	-	3	4	2-15
α-Fucosidase	23	35	2-26	0.7	0.8	0.4-2.7	2.6	4.3	≤0.41	0.5	1.1	1.1-7.6
α-Mannosidase	44	30	0.5-3	8.3	8.6	2-16	9.2	8.7	0.1-0.7	0.7	1.7	0.5-4.7
Arylsulphatase A	31	20	0.1-1.6	2.0	2.7	1-5	0.8	0.6	0.1-0.2	3.3	3.3	3.7-27
Acid phosphatase	9.3	5.9	5-33	55	52	20-160	2.0	2.2	0.6-1.4	41	40	14-30
β-Hexosaminidase A	5.9	-	0.4-2	6.1	-	4-11	-	-	-	-	-	-
β-Galactosidase	1.0	-	0.1-0.3	3.0	-	1-6	0.10	0.13	≤0.17	1.7	3.5	4-20
β-Glucosidase	-	-	-	-	-	-	5.6	6.0	0.1-0.4	-	-	-

^aNR, normal range.

In both subjects A and B, in the samples from peripheral blood, the plasma activities of several enzymes are high (**bold**), whereas intracellular (leukocyte) activities are normal, indicating leakage of lysosomal enzymes into the plasma. In the samples from cultured fibroblasts, a similar pattern is seen. The activities of several enzymes are high in the supernatant (extracellular). In contrast, the intracellular activities of many of these enzymes are low (*italic*). Note, however, the relatively high intracellular activity of the enzyme acid phosphatase, which is abundant in osteoclasts

measured at its midpoint, using a dial-gauge micrometer (by subtracting the medullary width from the total width).

Bone mineral content (BMC, g), and bone area (BA, cm²) were measured by dual x-ray absorptiometry (DEXA, Lunar DPX-L, Madison, WI, USA). Measurements were made at the lumbar spine in subject B, and at the forearm in subject A (spinal measurements were not possible in subject A because of deformity and mobility difficulties). From the lumbar spine measurements, the derived values of areal bone mineral density (aBMD = BMC/BA, g/cm²) and volumetric bone density (vBMD = aBMD/√BA, g/cm³) were calculated. Forearm measurements of BMC, bone width and the aBMD of a 1.5 cm length segment were made at both the ultradistal radius and ulna sites (predominantly trabecular bone), and the same measurements were made on a 2 cm length segment at both the 33% radius and ulna sites (predominantly cortical bone). Areal BMD values were also expressed as an age- and sex-matched standard deviation score (z-score) according to the manufacturer's database.

Transiliac bone biopsies (8 mm trephine) were taken before and after one year of monthly pamidronate infusions. Undecalcified sections were stained with von Kossa and Goldner's trichrome stain. Quantitative histomorphometry was undertaken using the OsteoMeasure system (Atlanta, GA, USA). The specimens were not tetracycline labelled.

Both subjects received monthly intravenous infusions of pamidronate: the initial dose given was 7.5 mg/m² body surface area, and subsequent doses were 15 mg/m², infused in 150 ml of saline over 4 h. Calcitriol, 0.25 µg twice a day and a daily oral calcium supplement were given for a week after each intravenous treatment.

RESULTS

Laboratory findings: Before treatment, serum calcium, phosphate and parathyroid hormone concentrations remained within age- and sex-specific reference ranges. Renal function remained normal. Plasma alkaline phosphatase activity and plasma osteocalcin concentrations were increased in both subjects before pamidronate treatment, as was the fasting urine hydroxyproline/creatinine ratio (Table 3).

Radiology and bone densitometry: Skeletal radiographs showed typical changes of dysostosis multiplex but also progressive erosive destruction of the hip joints and the superior endplates of the vertebrae (Figures 1 and 2). Both subjects had delayed skeletal maturation. At the time pamidronate treatment was started, the bone age of subject A was 17.2 years (chronological age 18.9), and the bone age of subject B was 12.9 years (chronological age 14.6).

Bone densitometry at the forearm in subject A showed reduced z-scores of -3.7 at the ultradistal radius (trabecular) site and -3.5 at the proximal radius (cortical) site. In subject B the z-scores were -3.1 at the lumbar spine (predominantly trabecular bone) and -2.1 for the whole body scan (predominantly cortical bone). These values are somewhat difficult to interpret in view of the short stature of both subjects. The estimated volumetric density of the lumbar spine in subject B was 0.278 g/cm³, which is close to the mean for this age.

Table 3 Biochemical indices of bone turnover before and during pamidronate therapy

	Time (months)	Subject A	Normal range ^a	Subject B	Normal range ^a
Alkaline phosphatase (i _u /L)	0	256	<120	453	<250
	6	187		316	
	12	156		237	
Osteocalcin (µg/L)	0	91	<50	116	<60
	6	81		94	
	12	51		49	
Hydroxyproline (µmol/mmol creatinine)	0	179	<33	133	<80
	6	102		185	
	12	72		113	
<i>N</i> -telopeptide (nmol BCE/mmol creatinine)	12	115	<51	170	<150

^aNormal values appropriate for age and sex

Bone histology: The findings in both subjects were similar. The most striking finding was of vigorous osteoclastic subperiosteal bone resorption occupying almost all the periosteal surface (Figure 3). There was evidence of active endosteal modelling with occasional osteoclasts and slight marrow fibrosis. Osteoid surfaces were increased in extent but were of normal thickness. The cortical widths were normal, but trabecular bone volumes were low in both subjects—more than three standards deviations below age-expected values (Glorieux et al 2000).

Effects of pamidronate therapy: Cyclic intravenous pamidronate treatment was well tolerated, apart from first-dose febrile responses, necessitating the admission of subject B to hospital for one night. Both subjects had a dramatic clinical response to pamidronate treatment, with both decreased pain and improved mobility. Subject A became almost completely pain free and able to assist in his wheelchair transfers. Subject B became pain free and had markedly improved mobility, being able to use crutches or a walking frame for moving about the house and garden, but still needing her wheelchair for longer trips. Both the patients and their parents reported a dramatic improvement in quality of life, including better sleep. Pubertal development in subject B proceeded normally, with menarche occurring a year after starting pamidronate.

No significant change in plasma calcium, phosphate or parathyroid hormone occurred during treatment. Markers of bone turnover were increased at baseline in both subjects, more so in subject B, whose growth was not yet complete. Some suppression of both urine hydroxyproline excretion and plasma alkaline phosphatase activity occurred during the first year's treatment with pamidronate, but in neither subject were normal values reached. Measurements of *N*-telopeptide/creatinine excretion made at the end of this period confirmed that bone resorption remained high (Table 3).

Repeat skeletal surveys taken after one year's pamidronate therapy showed increased bone density, particularly in the metaphyseal regions. The density of cortical

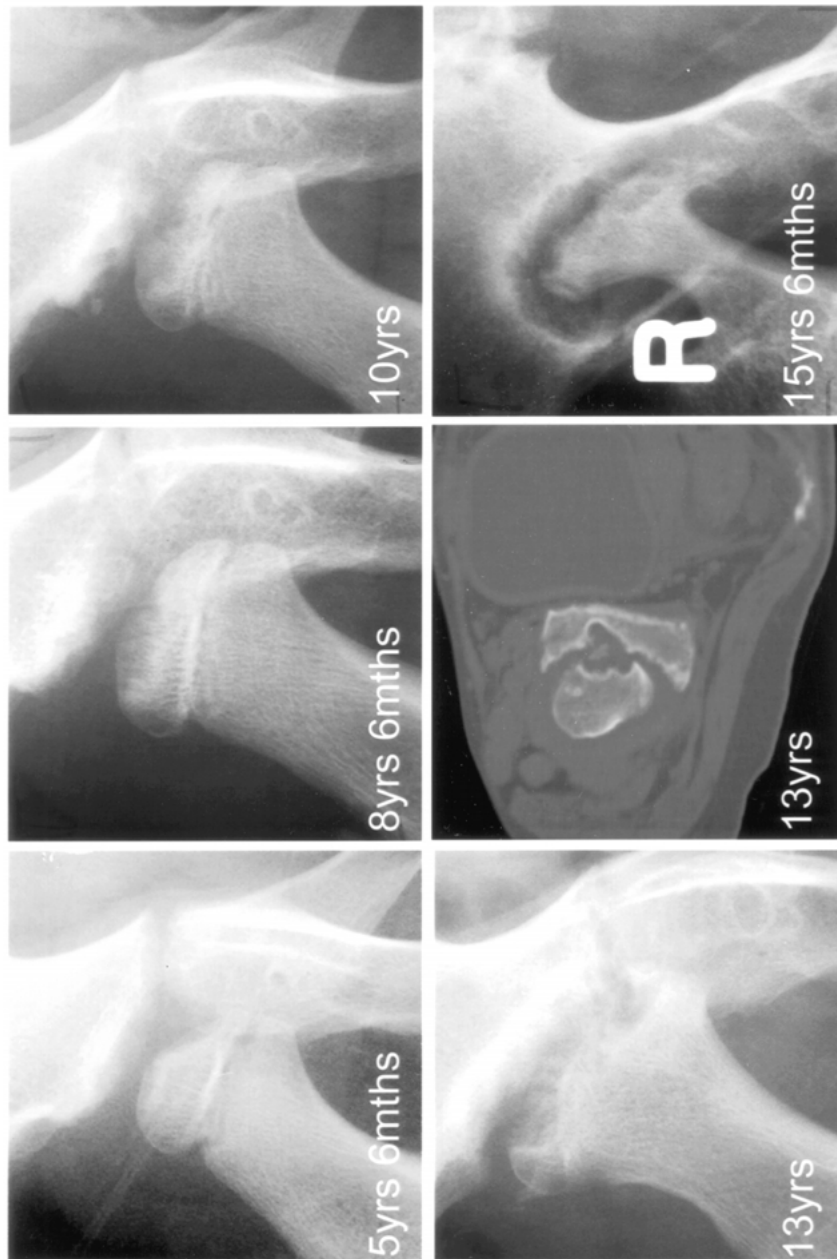

Figure 1 Radiographs of the right hip of subject B taken at ages 5½, 8½, 10, 13 and 15½ years, showing progressive erosion of the femoral head and the acetabulum. The final image, obtained after one year's pamidronate therapy, shows increased radiographic density but persistence of the erosive changes. The CT picture taken at age 13 years shows active bone destruction both of the femoral head and the acetabulum. The appearances were similar in subject A

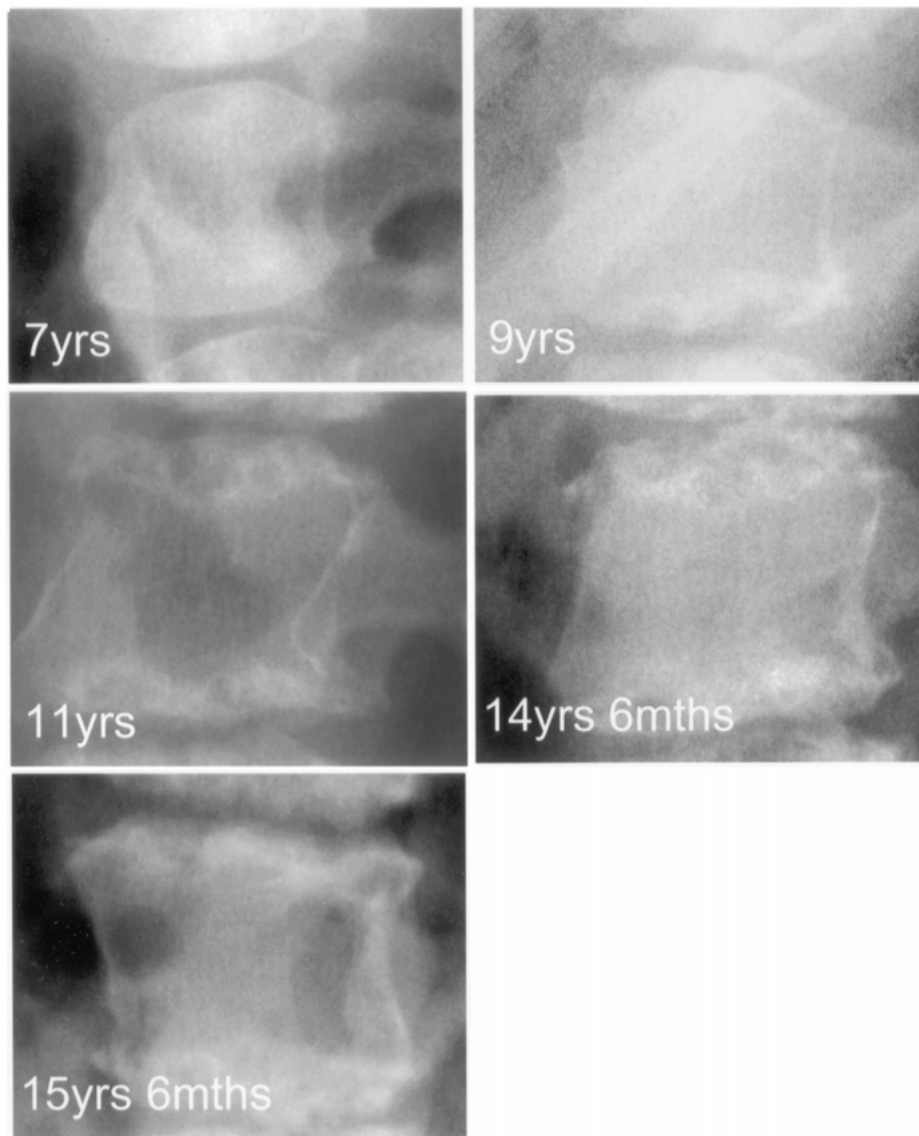


Figure 2 Lateral radiographs of the first lumbar vertebra of subject B, at ages 7, 9, 11, 14½, and 15½ years, showing the appearance of dysostosis multiplex in the early films, with anterior hypoplasia of the vertebral body, but also progressive erosion of the superior and inferior endplates. The final picture, obtained after one year's pamidronate therapy, shows increased radiographic density at the end plates, but persistence of the erosive changes. The appearances were similar in subject A

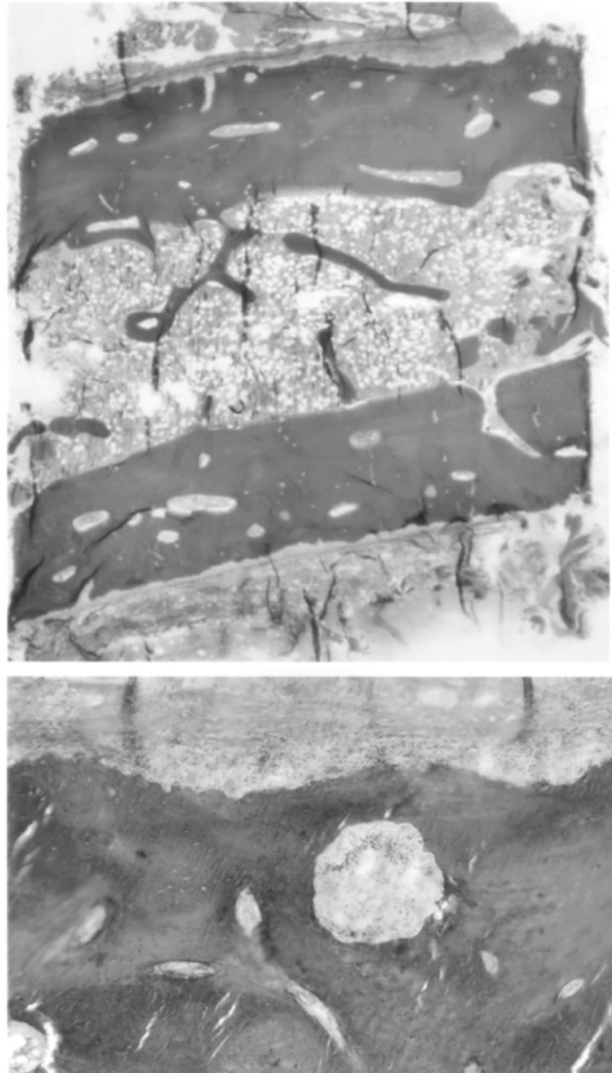


Figure 3 Bone histology from subject B, taken before pamidronate treatment. Goldner stain. The low-power view (top) demonstrates the very low trabecular bone volume (11%, more than 3 standard deviations below normal). On the high-power view (bottom), extensive osteoclastic resorption is visible all along the periosteal surface

bone also appeared to increase after pamidronate. The combined cortical width at the midpoint of the second metacarpal decreased by 7% in subject A and increased by 10% in subject B. The radiographic density of the femoral heads, acetabuli and vertebral endplates had increased, but the erosive changes had not changed significantly (Figures 1 and 2).

Bone densitometry was repeated 6-monthly. In subject A the BMC at the ultradistal radius and ulna sites (trabecular bone) showed increases of 50% and 76%, respectively, over one year, without change in bone width. At the proximal radius and ulna sites (cortical bone), BMC increased 18% and 29%, respectively, again with no change in bone width. At the ultradistal radius site, the areal bone density *z*-score increased from -3.7 to -0.1 . At the proximal radius site, it increased from -3.5 to -2.5 . In subject B the BMC of the 2nd–4th lumbar vertebrae increased by 70%, an effect partly arising from a 31% increase in estimated bone volume and partly from a 29% increase in estimated volumetric bone density. The areal bone density *z*-score increased from -3.1 to -1.4 .

Repeat bone biopsies after one year's therapy with pamidronate showed an essentially unchanged picture with vigorous subperiosteal bone resorption.

DISCUSSION

The two siblings that we studied both demonstrated the characteristic severe erosive bone disorder of ML III (Haddad *et al* 2000; Hetherington *et al* 1999; Kornfeld and Sly 2001; Melhem *et al* 1973), particularly affecting the femoral heads, acetabulae and vertebrae. The bone disorder was first evident radiographically around the age of 10 years and progressed relentlessly. The biochemical data indicate that both bone resorption and bone formation were increased, suggesting a "metabolic" bone disorder. The higher values of bone turnover markers in the younger sibling probably reflect the fact that her growth was less complete. The pathology of bone in ML III has not been reported before. The finding of marked bone resorption at the periosteal surface is quite distinctive. Similar findings were noted in the only published report of bone histology in the closely related disorder of mucopolipidosis II (Pazzaglia *et al* 1989). In that case, the similarity with the histological findings in osteitis fibrosa cystica led to the suggestion that hyperparathyroidism might be responsible for the subperiosteal bone resorption. However, the normal pretreatment plasma concentrations of calcium, phosphate and parathyroid hormone in our subjects make this implausible. Others have suggested that the changes at the femoral head represent osteonecrosis (Haddad *et al* 2000), but a recent study of the MRI appearances of the hip in ML III did not show characteristic features of osteonecrosis (Wihlborg *et al* 2000).

The finding of accelerated bone resorption is somewhat surprising. Although most of the lysosomal enzymes of osteoclasts are destined for secretion (rather than an intracellular function), mannose 6-phosphate signalling does appear to be important in osteoclasts. Mannose 6-phosphate (M-6-P) receptors are found in the endoplasmic reticulum, in the Golgi stacks, and in transport vesicles that fuse with the ruffled border membrane. M-6-P signalling appears to be involved in the trafficking of osteoclastic lysosomal enzymes to the apical membrane of the osteoclast, where they are secreted into the sealed, bone-resorbing compartment (Baron *et al* 1988). Thus, one might expect osteoclast activity to be reduced when there is defective M-6-P direction of the bone-resorbing enzymes. However, osteoclastic enzymes are meant to be secreted, so it is possible that, through leakage, greater than normal concentrations

accumulate within the sealed zone. Furthermore, not all bone-resorbing osteoclastic enzymes have M-6-P signalling. Acid phosphatase, for example, does not. It is synthesized as a transmembrane protein that is proteolysed to a soluble form on arrival in the lysosome, and is targeted to lysosomes by a pathway that does not require M-6-P (Barriocanal et al 1986; Kornfeld and Sly 2001). In the enzyme studies on cultured fibroblasts (Table 2), it is interesting to note that acid phosphatase activity was increased in the intracellular, as well as the extracellular, compartments, perhaps suggesting an increase in acid phosphatase synthesis.

Bisphosphonates are synthetic analogues of pyrophosphate that bind to the hydroxyapatite lattice of bone and are incorporated into the skeletal matrix. They are antiresorptive, an effect that is mediated via suppression of osteoclast numbers and function. The aminobisphosphonates are taken up by osteoclasts and incorporated into phosphorylated compounds within the mevalonate metabolic pathway. This interferes with the synthesis of geranylgeranyl diphosphate and fumaryl diphosphate, which in turn interferes with the membrane localization of small GTPases (Ras, Rho and Rac). These are important signalling proteins involved in transport processes in the osteoclast and also with isoprenylation of transported proteins (Rogers et al 2000).

The first description of bisphosphonate use in children was in 1969, in an attempt to treat myositis ossificans progressiva (Bassett et al 1969). In recent years bisphosphonates have been used safely, and with success, in children in a number of conditions including hypercalcaemia, fibrous dysplasia, and various osteoporotic disorders (Shoemaker 1999). A commonly reported finding in many of these studies of bisphosphonates in children is the marked analgesic effect on bone pain, which is often reported by patients and their caregivers early in the course of treatment. This phenomenon was certainly very noticeable in the subjects we studied. The cause of bone pain is uncertain, and the reason why bisphosphonates are effective is even more so. There are examples where the analgesic effects of bisphosphonates seem to be relatively dissociated from other effects. In both Gaucher disease and fibrous dysplasia, remarkable effects on bone pain can be observed with relatively little change in extent of the pathological lesions (Chapurlat et al 1997; Cianna et al 1997; Harinck et al 1984; Lala et al 2000; Ostlere et al 1991; Samuel et al 1994). In the subjects with ML III that we studied, it was notable that we obtained incomplete suppression of bone resorption as assessed by hydroxyproline and *N*-telopeptide excretion, and by bone histology. This is at variance with the findings in other types of paediatric bone diseases. We have subsequently used higher doses of intravenous pamidronate in our patients and still failed to suppress these markers of bone resorption (data not shown). The bone density data indicate that pamidronate did produce substantial effects—with increases in bone density particularly in trabecular bone-rich areas. Why bone resorption on the periosteal surfaces is so active, and why it is so difficult to suppress, are intriguing but currently unanswered questions.

In conclusion, we have presented evidence for the existence of a distinctive osteodystrophy in ML III. The use of intravenous pamidronate was associated with remarkable symptomatic improvement in bone pain, analgesic requirements and mobility, despite incomplete suppression of the abnormal bone turnover. Pamidronate therapy was well tolerated and safe.

ACKNOWLEDGEMENTS

We wish to thank Roland Baron for his helpful comments, and to acknowledge the assistance of the National Referral Laboratory for Lysosomal, Peroxisomal and Related Genetic Disorders, North Adelaide, South Australia for the diagnostic studies. Grace David is funded by a grant from the Connected committee, Australia.

REFERENCES

- Astrom E, Soderhall S (1998) Beneficial effect of bisphosphonate during five years of treatment of severe osteogenesis imperfecta. *Acta Paediatr* **87**: 64–68.
- Bassett CAL, Donath A, Macagno F, Preisig R, Fleisch H, Francis MD (1969) Diphosphonates in the treatment of myositis ossificans. *Lancet* **ii**: 845.
- Baron R, Neff L, Brown W, Courtoy PJ, Louvard D, Farquhar MG (1988) Polarized secretion of lysosomal enzymes: co-distribution of cation-independent mannose-6-phosphate receptors and lysosomal enzymes along the exocytic pathway. *J Cell Biol* **106**: 1863–1872.
- Barriocanal JG, Bonifacino JS, Yuan L, Sandoval IV (1986) Biosynthesis, glycosylation, movement through the Golgi system, and transport to lysosomes by an *N*-linked carbohydrate-independent mechanism of three lysosomal integral membrane proteins. *J Biol Chem* **261**: 16755–16763.
- Brumsen C, Hamdy NA, Papapoulos SE (1997) Long-term effects of bisphosphonates on the growing skeleton. Studies of young patients with severe osteoporosis. *Medicine* **76**: 266–283.
- Chapurlat RD, Delmas PD, Liens D, Meunier PJ (1997) Long-term effects of intravenous pamidronate in fibrous dysplasia of bone. *J Bone Miner Res* **12**: 1746–1752.
- Cianna G, Cuttini M, Bembi B (1997) Short-term effects of pamidronate in patients with Gaucher's disease and severe skeletal involvement. *N Engl J Med* **337**: 712.
- Glorieux FH, Bishop NJ, Plotkin H, Chabot G, Lanoue G, Travers R (1998) Cyclic administration of pamidronate in children with severe osteogenesis imperfecta. *N Engl J Med* **339**: 947–952.
- Glorieux FH, Travers R, Taylor A, et al (2000) Normative data for iliac bone histomorphometry in growing children. *Bone* **26**: 103–109.
- Haddad FS, Hill RA, Vellodi A (2000) Orthopaedic manifestations of mucopolipidosis type III: an illustrative case. *J Pediatr Orthop* **9**: 58–61.
- Harinck HI, Bijvoet OL, Van der Meer JW, Jones B, Onvlee GJ (1984) Regression of bone lesions in Gaucher's disease during treatment with aminohydroxypropylidene bisphosphonate. *Lancet* **ii**: 513.
- Hetherington C, Harris NJ, Smith TWD (1999) Orthopaedic management in four cases of mucopolipidosis type III. *J R Soc Med* **92**: 244–246.
- Kornfeld S, Sly WS (2001) I-cell disease and pseudo-Hurler polydystrophy: disorders of lysosomal enzyme phosphorylation and localization. In: Scriver CR, Beaudet AL, Sly WS, Valle D, eds; Childs B, Kinzler KW, Vogelstein B, assoc. eds. *The Metabolic and Molecular Bases of Inherited Disease*, 8th edn, vol III. New York: McGraw-Hill, 3469–3482.
- Lala R, Matarazzo P, Bertelloni S, Buzi F, Rigon F, de Sanctis C (2000) Pamidronate treatment of bone fibrous dysplasia in nine children with McCune–Albright syndrome. *Acta Paediatr* **89**: 188–193.
- Landsmeer-Beker EA, Massa GG, Maaswinkel-Mooy PD, van de Kamp JJP, Papapoulos SE (1997) Treatment of osteogenesis imperfecta with the bisphosphonate olpadronate (dimethylaminohydroxypropylidene bisphosphonate). *Eur J Pediatr* **156**: 792–794.
- Maroteaux P, Lamy M (1996) La pseudo-polydystrophie de Hurler. *Presse Med* **74**: 2889–2892.
- Melhem R, Dorst JP, Scott CI, McKusick VA (1973) Roentgen findings in mucopolipidosis III (pseudo-Hurler polydystrophy). *Radiology* **106**: 153–160.

- Ostlere L, Warner T, Meunier PJ, et al (1991) Treatment of type 1 Gaucher's disease affecting bone with aminohydroxypropylidene bisphosphonate (pamidronate) *Q J Med* **79**: 503–515.
- Pazzaglia UE, Beluffi G, Campbell JB, et al (1989) Mucopolipidosis II: correlation between radiological features and histopathology of the bones. *Pediatr Radiol* **19**: 406–413.
- Reitman ML, Varki A, Kornfeld S (1981) Fibroblasts from patients with I-cell disease and pseudo-Hurler polydystrophy are deficient in uridine 5'-diphosphate-*N*-acetylglucosamine: glycoprotein *N*-acetylglucosaminylphosphotransferase activity. *J Clin Invest* **67**: 1574–1579.
- Rogers MJ, Gordon S, Benford HL, et al (2000) Cellular and molecular mechanisms of action of bisphosphonates. *Cancer* **88** (supplement 12): 2961–2978.
- Samuel R, Katz K, Papapoulos SE, Yosipovitch Z, Zaizov R, Leiberman UA (1994) Aminohydroxypropylidene bisphosphonate (APD) treatment improves the clinical skeletal manifestations of Gaucher's disease. *Pediatrics* **94**: 385–389.
- Shoemaker LR (1999) Expanding role of bisphosphonate therapy in children. *J Pediatr* **134**: 264–267.
- Tanner JM, Whitehouse RH, Cameron N, Marshall WA, Healy MJR, Goldstein H (1983) *Assessment of Skeletal Maturity and Prediction of Adult Height*, 2nd edn. London. Academic Press.
- Wihlborg CEM, Babyn PS, Clarke JTR (2000) MRI appearances of hip abnormalities in mucopolipidosis type III. *Pediatr Radiol* **30**: 262–264.
- Zacharin M, Cundy T (2000) Osteoporosis pseudoglioma syndrome: treatment of spinal osteoporosis with intravenous bisphosphonates. *J Pediatr* **137**: 410–415.